

JULIA TRELEAVEN, PhD, BPhy¹

Dizziness, Unsteadiness, Visual Disturbances, and Sensorimotor Control in Traumatic Neck Pain



Symptoms such as dizziness, unsteadiness, and visual disturbances and signs of altered head and eye movement control and postural stability are common in those following neck trauma, especially in those with persistent pain.¹¹⁵ Understanding these signs and symptoms and potential origins is important for assessment and relevant rehabilitation. Suggested causes include altered sensorimotor control, vertebral artery dissection or insufficiency, psychosocial factors such as anxiety and

fear avoidance, and medication use.^{34,107,113} Among these factors, research to date indicates that the primary cause is most likely altered sensorimotor control.¹¹⁴

The sensorimotor control system comprises input from the visual, vestibular, and proprioceptive systems, particularly the richly innervated cervical spine, which is integrated in the central nervous

system (CNS) to provide appropriate motor output to control head and eye movement and postural stability.⁵ Potential damage or impairment to components of the sensorimotor control system (cervical spine, vestibular system, or CNS) is possible following traumatic incidents such as a whiplash injury. However, based on animal and human models, in

incidents of relatively low force (ie, low speed and no concussion, loss of consciousness, or a direct blow to the head), sensorimotor control disturbances due to CNS or peripheral vestibular system injury are less likely,^{43,104,107} in contrast to the more likely damage and subsequent functional impairment of the abundant cervical joint and muscle structures and related receptors.^{51,111,129} These cervical receptors provide important input and have unique central and reflex connections to the vestibular, visual, and sensorimotor control systems (FIGURE 1).^{18,82}

After traumatic neck injury, disturbances in sensorimotor control, primarily via altered cervical input, may occur due to a combination of factors. Apart from direct trauma, factors associated with the trauma, such as inflammation,¹¹⁰ functional impairment,³² morphological changes to musculature,²⁹ pain,⁶⁶ and psychological distress,⁷⁹ may alter cervical input or CNS representation. This can influence cervical reflex connections to the visual and vestibular systems and result in subsequent secondary disturbances.⁹⁷ Immediate sustained change in cervical input to the sensorimotor control system following neck trauma may be a more common cause of dizziness, visual disturbances, and unsteadiness, as well as changes in cervical proprioception, head and eye movement control, and postural stability, although other causes of senso-

● **SYNOPSIS:** There is considerable evidence to support the importance of cervical afferent dysfunction in the development of dizziness, unsteadiness, visual disturbances, altered balance, and altered eye and head movement control following neck trauma, especially in those with persistent symptoms. However, there are other possible causes for these symptoms, and secondary adaptive changes should also be considered in differential diagnosis. Understanding the nature of these symptoms and differential diagnosis of their potential origin is important for rehabilitation. In addition to symptoms, the evaluation of potential impairments (altered cervical joint position and movement sense, static and dynamic balance, and ocular mobility and coordination) should become an essential part of the routine

assessment of those with traumatic neck pain, including those with concomitant injuries such as concussion and vestibular or visual pathology or deficits. Once adequately assessed, appropriate tailored management should be implemented. Research to further assist differential diagnosis and to understand the most important contributing factors associated with abnormal cervical afferent input and subsequent disturbances to the sensorimotor control system, as well as the most efficacious management of such symptoms and impairments, is important for the future. *J Orthop Sports Phys Ther* 2017;47(7):492-502. doi:10.2519/jospt.2017.052

● **KEY WORDS:** cervical spine, proprioception, WAD, whiplash

¹Neck Pain and Whiplash Research Group, Division of Physiotherapy, School of Health and Rehabilitation Sciences, University of Queensland, St Lucia, Australia. The author certifies that she has no affiliations with or financial involvement in any organization or entity with a direct financial interest in the subject matter or materials discussed in the article. Address correspondence to Dr Julia Treleaven, Division of Physiotherapy, School of Health and Rehabilitation Sciences, University of Queensland, St Lucia, QLD 4072 Australia. E-mail: j.treleaven@uq.edu.au ● Copyright ©2017 *Journal of Orthopaedic & Sports Physical Therapy*®

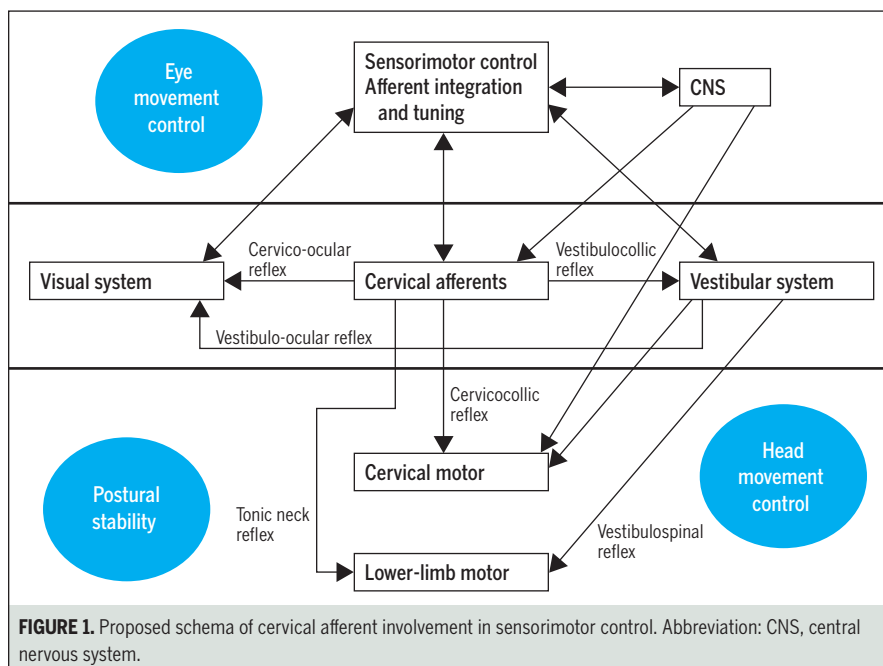


FIGURE 1. Proposed schema of cervical afferent involvement in sensorimotor control. Abbreviation: CNS, central nervous system.



FIGURE 2. Cervical joint position error in neck torsion. A laser is placed on the sternum and projected onto a target 90 cm away. The head is gently held still by the examiner while the individual actively rotates the trunk as far as comfortable and then returns to the starting position as accurately as possible with vision occluded. The difference in degrees between the starting and ending positions is the joint position error.

rimotor control disturbances should also be considered in the differential diagnosis process. The present commentary will explore current evidence for symptoms and signs, clinical assessment, differential diagnosis, and management of sensorimotor control disturbances associated with traumatic neck pain.

EVIDENCE OF SENSORIMOTOR DISTURBANCE

Symptoms

SYMPTOMS CHARACTERISTIC OF CERVICOGENIC dizziness and unsteadiness are often present in patients following neck trauma, especially in those with persistent pain.^{114,121} True vertigo or spinning, typically attributed to vestibular dysfunction, is rarely described, and generally the dizziness is described as vague unsteadiness or light-headedness.¹²¹ Further, exacerbating factors are generally related to increased neck pain, headache, or neck-related movement and activity.^{114,121} Such symptoms have also been associated with reports of loss of balance and falls in some individuals.¹²¹

Symptoms relating to the visual system, such as needing to concentrate to

read, visual fatigue, difficulty judging distances, and light sensitivity, are frequently reported in whiplash-associated disorder (WAD) and idiopathic neck pain (INP) without trauma.¹²⁴ Interestingly, these are symptoms similar to those experienced by some individuals with postconcussion syndrome, additional visual symptoms, such as losing the location on the page and ineffective reading speed, are also often reported.^{61,98} Also, true double vision, which is common in individuals with vertebrobasilar insufficiency, is not commonly reported in traumatic neck pain.¹²⁴

Interestingly, other symptoms often associated with postconcussion syndrome,⁶¹ such as headache, poor concentration,¹⁰⁵ and fatigue,¹⁰⁶ are also common in those with traumatic neck pain. It is possible that this is due to concomitant head trauma associated with neck trauma or vice versa, where potential neck trauma is associated with head trauma.^{30,62,69}

Cervical Proprioception

Joint Position Sense Joint position sense (JPS) is defined as the ability to relocate the natural head position without the as-

sistance of vision.⁸⁸ Greater errors have been shown in individuals with both INP and persistent WAD, although errors are greater in those with neck trauma,²⁴ especially in those with moderate to severe pain and disability.¹⁰⁰ Further, Treleven et al¹²¹ found that individuals with persistent WAD and symptoms of dizziness had greater errors than those not complaining of dizziness, suggesting that these symptoms may be due to greater abnormal cervical afferent input. However, while JPS testing is thought to be a measure of cervical proprioception, deficits have also been seen in those with vestibular pathology in some¹¹⁴ but not other studies.⁶⁷ More recently, to better control for vestibular function, an alternative test of trunk relocation on a stable head has been developed (**FIGURE 2**). Although the test has promise to assist with differential diagnosis, additional research is required before it can be advocated for clinical and research use.¹² Interestingly, position sense deficits have not been isolated to the neck in this population, with deficits also seen in the shoulder and elbow in some patients with traumatic neck pain.^{57,91}

Cervical Movement Accuracy Several studies have looked at accuracy of fine motion control in the neck of those with traumatic neck pain as another measure of proprioception. Kristjansson et al⁵⁹ and Kristjansson and Oddsdottir⁶⁰

demonstrated less accuracy in tracing a computer-generated movement pattern with the head in those with traumatic neck pain when compared to both a control group and individuals with INP. These authors also found that these impairments did not specifically relate to other signs and symptoms associated with WAD and seem to either develop over time or persist.⁷⁶ Woodhouse et al,¹³² using a stationary movement pattern, also demonstrated decreased accuracy in individuals with WAD compared to a control group and individuals with INP. Recently, accuracy in following a moving target in a virtual environment has been shown to be somewhat sensitive and specific to those with neck pain.⁴ To date, no specific differences in those with traumatic neck pain compared to INP have been noted, but this is a continued area of investigation (FIGURE 3).⁴

Vertical Alignment Perception Disturbances in the ability of individuals with neck pain to correctly identify true vertical using the rod and frame test are thought to be suggestive of disturbed cervical proprioception.³ It has been suggested that those with traumatic neck pain may have greater deficits. But, a recent study demonstrated altered vertical perception in those with INP but not WAD.¹²⁵ It was suggested that this might have been due to the complexity of the

measure; therefore, as is, vertical alignment perception may not be a suitable measure of cervical proprioception in those with traumatic neck pain.¹²⁵

Standing Balance

Static Balance Several studies have demonstrated disturbed postural stability in individuals with traumatic neck pain,^{8,68,95,96} especially in those with symptoms of dizziness.¹²⁰ Balance disturbances have also been related to neck muscle fatigue in those with WAD.⁹⁹ Deficits are noted in most testing conditions, including when standing in comfortable, narrow, and tandem stances, and especially when vision is occluded. Sway is usually increased in the anterior-posterior direction, indicative of somatosensory impairment,⁹⁴ although in more difficult tests, a stiffening strategy and less sway, compared to those with INP, has been observed.⁹⁶ These static balance disturbances are likely primarily due to cervical afferent dysfunction rather than vestibular function, as they differ in those with unilateral vestibular pathology.¹²² In addition, individuals with WAD, in a test specifically designed to isolate the cervical afferents, had increased sway with the neck in a torsioned (trunk turned, head still), rather than in a head-rotated, position when compared to a neutral head position.¹³³ These alterations were not seen in either asymptomatic individuals or those with vestibular pathology.^{127,133} This suggests that this test may be specific for those with cervical-related balance deficits.

Dynamic and Functional Balance Dynamic and functional balance can also be affected. Impairments in the step test, timed 10-m walk with and without head turns, tandem walk, and stair walking, as well as delayed corrective responses to destabilizing perturbations while sitting and stepping in place, have been demonstrated in those with persistent WAD.^{13,19,101} Interestingly, similar patterns of balance impairment were present in individuals with traumatic neck pain with and without concussion, but those with concussion had greater balance defi-

cits for stance and complex rather than simple gait tasks.⁹⁶ This may suggest a combined cervical/vestibular deficit in this population.

Eye Movement Control

Several alterations in oculomotor control, including disturbed eye follow, gaze stability, eye-head coordination, vergence, saccades, and ocular reflex activity, have been associated with traumatic neck pain. Such abnormalities can be present in disorders of the vestibular system, disorders of the CNS, and as a result of abnormal afferent input from the cervical spine.^{47,73,119}

Smooth-Pursuit Neck Torsion

Similarly to balance tests, neck torsion has been used to demonstrate a cervical afferent cause in some tests. Accordingly, abnormalities in eye follow or smooth pursuit when tested in the neck torsion position, compared to a neutral neck position, have been seen in those with WAD but not in those with central or peripheral vestibular pathology.^{111,122} These abnormalities were also greater in those with whiplash who also had symptoms of dizziness.¹¹⁹ In other studies, close associations were noted between performance on the smooth-pursuit neck torsion (SPNT) test and disturbance of reading, driving, and cognitive tasks.⁴¹ This suggests that some common symptoms of posttraumatic neck injury might manifest from disturbed sensorimotor control due to abnormal cervical afferent input. However, others using a fully automated analysis of SPNT^{26,54,58} have not found deficits to the same extent. This may reflect the importance of trained observers to determine and extract the appropriate elements of the signal for analysis. A test to address this problem may be the cervical torsion test. Recently, it has been suggested that nystagmus of greater than 2°/s during sustained neck torsion positions may be an alternative and more sensitive method than SPNT to demonstrate these abnormalities.⁶⁷ However, this was done in individuals with cervicogenic diz-



FIGURE 3. Cervical movement accuracy. The individual follows a moving target at 10°/s in flexion, extension, and rotation to the left and right while immersed in a virtual reality environment. Sensors in the head-mounted display measure the difference between the target and the individual's head position to give a measurement of accuracy.

ziness and not specifically in those with traumatic neck pain.

While abnormalities in smooth pursuit with the neck in torsion have been linked with cervical afferent disturbances, it is possible that smooth-pursuit abnormalities in the neutral neck position or altered saccadic eye movement may reflect CNS impairment,¹³⁰ which can occur in isolated severe cases of persistent pain following neck trauma.¹²⁹ Further, medications and some psychological conditions can influence eye movement control, although this should not be influenced by neck positions such as neck torsion.³⁹

Gaze Stability Decreased range of head movement while attempting gaze fixation, measured by head and eye movement sensors, has also been seen in those with traumatic neck pain.^{44,117} Recently, physical therapists' ratings of visually assessed head and eye movement control tests, such as gaze stability, were shown to be reliable and also demonstrated impairments in those with neck pain, which included traumatic neck pain,²² enabling clinical application of these measures. However, unlike SPNT, there is not yet a specific test to isolate a cervical afferent cause of gaze stability disturbances.

Ambient Visual System Damage to the ambient visual system, important for spatial orientation, has also been suggested as a possibility following a whiplash injury.⁷⁸ Convergence and accommodation insufficiency and eye alignment malfunctions have been demonstrated in some following a whiplash injury.^{11,102} Together, these symptoms can be labeled as post-trauma visual syndrome.⁷⁸ Nevertheless, research into this area is in its infancy. In those with concussion, more work has been done, and oculomotor deficits, thought to be related to cortical or sub-cortical function, have been shown to be common, especially early postinjury,^{80,128} and may be a persistent feature in some.⁴⁸

Cervico-ocular Reflex An increased gain of the cervico-ocular reflex has also been demonstrated in individuals with whiplash⁷⁰ and recently in those with INP,²³ supporting the theory of cervical afferent

disturbance as the cause of the deficits. Interestingly, when this is seen in people with vestibular pathology and in the elderly, it is thought to be a compensation for a decrease in vestibulo-ocular reflex gain.⁷¹ However, this compensatory response has not been seen in individuals with WAD and may be an important cause of disturbances to the visual system.⁷¹ Further, there is some evidence that reflexive neck muscle activity seen during eye movements, likely mediated by this reflex, is altered in those with WAD.⁷

Eye-Head-Body Coordination

Decreased head velocity during tasks involving head-eye coordination, compensatory head movements during isolated eye rotation,¹¹⁷ reduced precision in an eye-head-hand coordination task,⁹² and impairment in trunk-head coordination (ie, moving the head and trunk independently) have been identified in those with traumatic neck pain.¹²⁶

Sensorimotor Incongruence

Sensorimotor integration has been suggested to be affected in those with traumatic neck pain as a result of impaired cervical proprioception and has been assessed via altered perception of distorted visual feedback or laterality judgment tasks. During a distorted arm coordination task, sensorimotor incongruence was seen in those with both acute and chronic traumatic neck pain.^{20,21} However, a study using laterality judgment tasks did not show impairments,⁸¹ and another, in fact, found improved reaction times and similar accuracy to controls in those with traumatic neck pain.⁹⁰ The authors of the later study suggest that strategies to compensate for altered proprioception may have led to this finding.

PREDICTORS OF POOR RECOVERY

THERE IS SOME EVIDENCE THAT symptoms such as dizziness and signs of sensorimotor control disturbances may be indicative of poorer

prognosis in those with traumatic neck pain.^{15,50,77,83,100} Thus, appropriate assessment, differential diagnosis, and management of clinical features may be important, especially when trying to prevent transition to chronicity.¹¹³

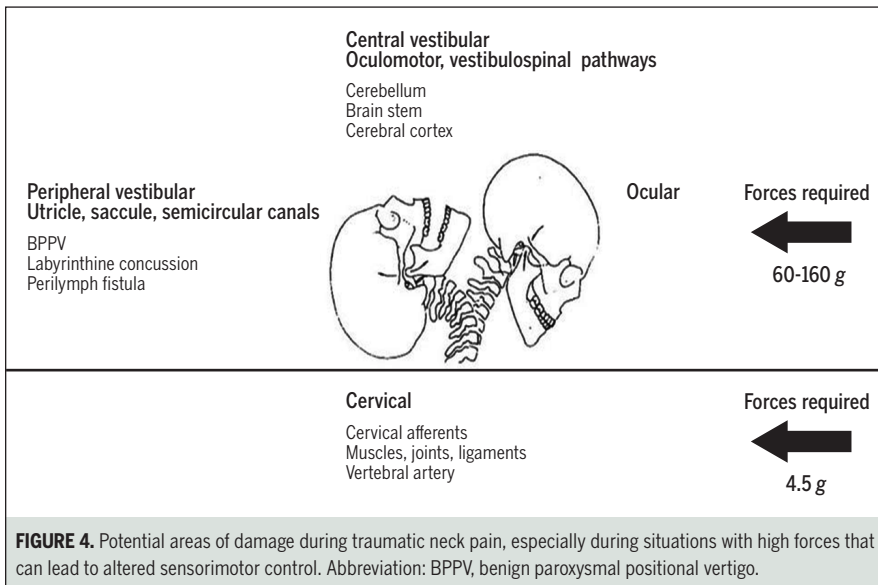
CLINICAL ASSESSMENT

GIVEN THE CURRENT EVIDENCE, EARLY assessment of cervical joint position and movement sense, balance, and oculomotor and coordination disturbances^{55,115} should be routine in all patients with traumatic neck pain, not just in those complaining of symptoms. There is evidence that these features occur soon after injury and are not a response to ongoing pain and disability.^{14,51,100} While there is abundant evidence that these signs and symptoms are most likely due to altered cervical afferent input to the sensorimotor control system, in some individuals, there is potential for other causes, and thus differential diagnosis is important to direct appropriate management. Other considerations are the potential for primary cervical afferent disturbances leading to secondary vestibular impairments,^{37,97} primary vestibular or visual impairments influencing the cervical spine,^{2,89,131} and the presence of concomitant cervical, visual, vestibular, and or mild brain deficits such as those seen following concussion.^{30,69}

DIFFERENTIAL DIAGNOSIS

IT CAN BE DIFFICULT TO PRECISELY determine the causes of sensorimotor control disturbances in those with traumatic neck pain due to potential concomitant deficits (visual or vestibular), as well as secondary adaptations within the sensorimotor control system. Further, certain medications and factors such as anxiety can perpetuate or cause disturbances via several suggested mechanisms.^{39,79}

It is important to consider that even in low-force situations generated during traumatic neck injury, there is potential



for vestibular migraine should also be considered in the chronic phase.^{63,64} Referral for a more thorough investigation of the vestibular, CNS, or visual systems and appropriate medical management may then be warranted.

At present, consensus opinion is that tests to identify vestibular or CNS dysfunction have stronger clinical utility than tests for cervical causes of dizziness and sensorimotor control disturbances.⁸⁷ Nevertheless, there are some emerging objective tests that may also help differential diagnosis of cervicogenic causes of the disturbances, with a cluster of tests likely to be more discriminatory than individual tests.⁶⁷ For example, tests of smooth pursuit,^{111,119} balance,¹³³ and JPS¹² in torsion (head still, trunk rotated) may be useful in indicating the extent of the cervical spine contribution to the deficits. This is expected when signs and symptoms are increased when the individual is positioned in torsion compared to the neutral neck position. Similarly, in a recent study, the cervical torsion test was found to be one of a cluster of useful discriminating tests for cervicogenic dizziness. In this test, the head is held still and the patient rotates the trunk to the left, then returns to neutral, then rotates the trunk to the right, and finally returns to neutral. Each position is sustained for 30 seconds, and nystagmus of greater than 2°/s in any of the 4 positions is considered a positive test.⁶⁷ Conversely, reproduction of symptoms during en bloc tests (ie, simultaneous trunk and head rotation) should indicate a noncervical cause.⁴⁹ Associated findings of musculoskeletal impairment in the cervical spine, especially the upper cervical spine, have been shown to be important in those with cervicogenic dizziness^{67,86}; however, this is usually present in those with traumatic neck pain and thus not specifically helpful for differential diagnosis in this group. A potential schema for differential diagnosis, possible subjective and objective test findings, and subsequent management that may be required are presented in the **TABLE**.

damage to many neck structures,¹⁰⁷ including the vertebral artery. Although vertebral artery dissection is rare, it is potentially dangerous^{9,56} and should always be considered in the differential diagnosis. Recent work by Thomas¹⁰⁸ and Thomas et al¹⁰⁹ suggests that this should be suspected, particularly in those with severe unilateral neck pain and headache and those who report transient or ongoing specific neurological dysfunction.

However, when higher forces or a direct blow to the head occur, additional injuries, such as concussion and/or damage to the CNS or visual or peripheral vestibular apparatus, are more likely (**FIGURE 4**).⁷⁴ It has been suggested that up to 35% of those with traumatic neck pain associated with higher forces may have peripheral vestibular damage (eg, benign paroxysmal positional vertigo, damage to the endolymphatic sac, or a perilymph fistula).^{25,31,43,112} Further, there is some suggestion that injuries induced by axial rotation versus linear acceleration during the accident may result in different types of neuro-otological injury.⁴⁰ Vestibular migraine might also be triggered by the injury associated with traumatic neck pain.^{65,72} Conversely, in those who have a primary diagnosis of concussion, associated neck trauma should also be considered as a potential cause of some symptoms.^{30,69} Thus,

the clinician should interview the patient and choose tests accordingly to consider these possible causes of the disturbances and to determine the most likely cause.

In general, cervicogenic dizziness should be episodic, have a close temporal relationship to neck pain, be brought on by specific neck movements or positions rather than whole-body movements or other factors such as increased intracranial pressure or anxiety, and be described as an unsteadiness or light-headedness, not vertigo. Thus, the description, temporal pattern, and aggravating factors of the symptoms,^{16,17,53,121} as depicted in the **TABLE**, can be useful to determine the need for additional tests, such as the head thrust or head impulse test, and head shaking nystagmus, dynamic visual acuity for peripheral vestibular pathology, or the Dix-Hallpike or head-roll maneuvers for benign paroxysmal positional vertigo.⁴⁹ Spontaneous and gaze-evoked nystagmus, as well as other oculomotor tests such as eye tracking, skew deviation, and saccades, may be required if central vestibular pathology or brain injury is suspected.^{38,49} Tests of accommodative function such as near-point convergence, often positive in those with concussion, should be included in those with visual symptoms exacerbated by eye movements alone.^{42,80} The diagnostic criteria

TABLE

DIFFERENTIAL DIAGNOSIS AND SUGGESTED MANAGEMENT OF SENSORIMOTOR CONTROL DISTURBANCES IN THOSE WITH TRAUMATIC NECK PAIN

	Cervical	Vertebral Artery	BPPV	Perilymph Fistula	Peripheral Vestibular	Central Vestibular	Psychological
Description	<ul style="list-style-type: none"> • Unsteadiness • Light-headedness 	<ul style="list-style-type: none"> • Fainting • Vertigo dizziness 	<ul style="list-style-type: none"> • Vertigo 	<ul style="list-style-type: none"> • Vertigo • Dysequilibrium • Motion intolerance 	<ul style="list-style-type: none"> • Vertigo • Unsteadiness • Motion intolerance 	<ul style="list-style-type: none"> • Dysequilibrium • Motion intolerance 	<ul style="list-style-type: none"> • Floating • Rocking • Fullness in head
Frequency	<ul style="list-style-type: none"> • Episodic 	<ul style="list-style-type: none"> • Episodic 	<ul style="list-style-type: none"> • Discrete attacks 	<ul style="list-style-type: none"> • Episodic/constant 	<ul style="list-style-type: none"> • Episodic vertigo • Constant unsteadiness 	<ul style="list-style-type: none"> • Varies 	<ul style="list-style-type: none"> • Varies
Duration	<ul style="list-style-type: none"> • Minutes to hours 	<ul style="list-style-type: none"> • Several seconds 	<ul style="list-style-type: none"> • Seconds 	<ul style="list-style-type: none"> • Constant 	<ul style="list-style-type: none"> • Seconds to minutes 	<ul style="list-style-type: none"> • Varies 	<ul style="list-style-type: none"> • Varies
Exacerbated	<ul style="list-style-type: none"> • Increasing neck pain • Neck movement 	<ul style="list-style-type: none"> • Sustained neck extension and/or rotation 	<ul style="list-style-type: none"> • Rolling in bed • Looking up • Lying down 	<ul style="list-style-type: none"> • Visual challenges • Increased intracranial or atmospheric pressure (eg, blowing nose) • Loud noises 	<ul style="list-style-type: none"> • Head positions or movement 	<ul style="list-style-type: none"> • Spontaneous or provoked 	<ul style="list-style-type: none"> • Stress • Anxiety • Hyperventilation
Relieved	<ul style="list-style-type: none"> • Decreasing neck pain 	<ul style="list-style-type: none"> • Neck back to neutral 	<ul style="list-style-type: none"> • Subsides if staying in provoking position 	<ul style="list-style-type: none"> • Avoiding above activities, rest 	<ul style="list-style-type: none"> • Head/body still 	<ul style="list-style-type: none"> • Varies 	<ul style="list-style-type: none"> • Relaxation
Associated symptoms	<ul style="list-style-type: none"> • Blurred vision • Nausea • Neck pain 	<ul style="list-style-type: none"> • Dysarthria • Hemiparesis • Dysesthesia • Diplopia • Dysphagia • Drop attacks • Nystagmus • Nausea • Numbness 	<ul style="list-style-type: none"> • Nausea • Vomiting 	<ul style="list-style-type: none"> • Unilateral tinnitus • Aural pressure • Hearing loss 	<ul style="list-style-type: none"> • Nausea • Vomiting • Hearing loss • Tinnitus • Ear fullness 	<ul style="list-style-type: none"> • Nausea • Imbalance • CNS signs 	<ul style="list-style-type: none"> • Lump throat • Heart palpitations • Tight chest
Suggested cause	<ul style="list-style-type: none"> • Abnormal cervical afferent input 	<ul style="list-style-type: none"> • VA dissection/insufficiency 	<ul style="list-style-type: none"> • Debris in endolymph 	<ul style="list-style-type: none"> • Leak of perilymph fluid into middle ear 	<ul style="list-style-type: none"> • Vascular injuries • Fractures 	<ul style="list-style-type: none"> • Brain stem • Cerebellum 	<ul style="list-style-type: none"> • Anxiety • Stress
Primary objective findings	<ul style="list-style-type: none"> • Cervical musculoskeletal impairments • JPE, >4.5° • Increased sway • Balanced neck torsion • Positive SPNT • Positive cervical torsion test • Positive trunk-head coordination test • Absence of other findings 	<ul style="list-style-type: none"> • Possible positive VBI tests • VAD: unilateral severe headache • Transient neurological disturbances relating to VA function 	<ul style="list-style-type: none"> • Positive Dix-Hallpike or head roll 	<ul style="list-style-type: none"> • Positive pressure test • Positive Valsalva test 	<ul style="list-style-type: none"> • Head impulse • Head-shake DVA 	<ul style="list-style-type: none"> • Spontaneous or gaze-evoked nystagmus • Oculomotor deficits* • Ataxia 	<ul style="list-style-type: none"> • None
Suggested treatment	<ul style="list-style-type: none"> • Cervical musculoskeletal and tailored sensorimotor 	<ul style="list-style-type: none"> • Referral to neurologist 	<ul style="list-style-type: none"> • Epley or BBQ roll maneuver 	<ul style="list-style-type: none"> • Referral to ENT • Surgery 	<ul style="list-style-type: none"> • Tailored vestibular rehabilitation, central adaptation, habituation • Cervical musculoskeletal and tailored sensorimotor as required 	<ul style="list-style-type: none"> • Tailored rehabilitation, oculomotor, vestibular, balance, and gait • Cervical musculoskeletal and tailored sensorimotor as required 	<ul style="list-style-type: none"> • Meditation • Mindfulness • Stress management • Cervical musculoskeletal and tailored sensorimotor as required

Abbreviations: BBQ, barbeque; BPPV, benign paroxysmal positional vertigo; CNS, central nervous system; DVA, dynamic visual acuity; ENT, ear-nose-throat specialist; JPE, joint position error; SPNT, smooth-pursuit neck torsion; VA, vertebral artery; VAD, vertebral artery dissection; VBI, vertebral basilar insufficiency. *Oculomotor includes skew deviation, vergence, smooth pursuit, and saccades.

IMPLICATIONS FOR MANAGEMENT

GIVEN THE ABOVE AND THE CLOSE connections and adaptations involved in the sensorimotor control system, management of these disturbances is likely to be multimodal and may need to address not only the primary causes but also secondary adaptive changes in the sensorimotor control system. It would seem that this should be tailored to the individual and based on his or her specific self-reports and objective findings (TABLE). Overlap in conventional management approaches may therefore occur, for example, making use of vestibular rehabilitation strategies, but again, the management approach is likely to be more effective if it is a problem-oriented, tailored, evidence-based approach. It should also be pointed out that when neck pain is associated with vestibular pathology, often there is a need to address the cervical musculoskeletal impairments so that the individual is able to effectively complete the exercises for vestibular rehabilitation, as often this requires repetitive fast head/neck motion. The authors of a recent study have indeed demonstrated the benefits of including a musculoskeletal intervention in those with peripheral vestibular pathology.¹³¹

Cervical Musculoskeletal Management

Several studies have demonstrated improvements in dizziness and/or sensorimotor control in those with traumatic neck pain following treatment only targeted to the cervical spine, which likely addressed some of the causes of altered cervical afferent input. Acupuncture has been shown to improve cervical JPS, dizziness,⁴⁶ and standing balance,³³ and improvements in dizziness and JPS have also been demonstrated following manual therapy.⁴⁶ Further, cervical muscle endurance training improved balance in individuals with whiplash.⁹⁹ Nevertheless, while a recent clinical trial focusing on specific neck muscle exercises combined with a behavioral approach dem-

onstrated improved dizziness in those with whiplash, many continued to have symptoms of dizziness and signs of balance impairment following the intervention.¹²³ Similarly, in a study of individuals with cervicogenic dizziness, while dizziness improved with manual therapy, changes in JPS and balance were negligible.^{85,86} These findings suggest that additional interventions directed toward these specific other impairments may need to be considered.

Addressing Adaptive Changes in the Sensorimotor Control System

There is some evidence that specific treatment programs that emphasize gaze stability, eye-head coordination, and/or head-on-trunk relocation, without including local cervical spine treatment, have resulted in improvements not only in sensorimotor impairments but also in neck pain and/or perceived disability in those with traumatic neck pain.^{52,102,116} Vestibular rehabilitation programs have been shown to be useful in those with concussion^{1,45} and resulted in improved balance and dizziness in individuals with WAD.²⁷ Interestingly, in those with WAD, this training did not improve neck pain or movement.²⁸ Thus, such an approach provided in isolation may not be able to address all of the deficits or be the most efficient approach.

Combined Cervical Musculoskeletal Treatment and Structured Sensorimotor Approach

Studies that have included eye-head coupling and coordination exercises as part of a multimodal approach have demonstrated improvements in neck pain and JPS.^{46,84} A pilot trial of a combined approach demonstrated significant improvements in postural stability in those with chronic whiplash.⁷⁵

Combined Cervical Musculoskeletal and Tailored Sensorimotor Approach

While a combined approach may be more suitable, the lack of direct correlation between sensorimotor measures^{103,118}

would imply that treatment directed towards improving, for example, eye movement control may not necessarily be the most effective to improve balance or JPS. Thus, a tailored sensorimotor approach with exercises aimed to improve identified deficits in cervical joint position and movement sense, oculomotor function, and static and dynamic balance may be superior and is currently recommended clinically.^{55,114,115} A similar combination of cervical musculoskeletal and vestibular interventions has been shown to decrease time to return to sport in young adults with persistent symptoms of dizziness, neck pain, and headaches following concussion.⁹³ Others agree that this combined tailored approach would seem most suitable in those with concussion with associated neck trauma.^{10,30,69} Recently, an opinion piece also highlighted the potential of vision therapy as a component in the management of these patients.⁶ This area of research is in its infancy and should be considered in future studies.

CONCLUSION

THERE IS CONSIDERABLE EVIDENCE to support the importance of cervical afferent dysfunction in the development of dizziness, unsteadiness, visual disturbances, and altered balance, eye, and head movement control following neck trauma, especially in those with persistent pain. A thorough evaluation is required to also consider other possible causes and secondary adaptive changes in the process of differential diagnosis. It is important that such symptoms and impairments be adequately assessed and tailored management be implemented. This should become an essential part of the routine assessment and management of those with traumatic neck pain, including those with concomitant injuries such as concussion, vestibular system damage, and visual pathology or deficits. Ongoing research to assist differential diagnosis and to understand the most important contributing factors associated with abnormal cervical input

and subsequent disturbances to the sensorimotor control system, as well as the most efficacious management of such symptoms and impairments, continues to add to our knowledge. ●

REFERENCES

- Alsalaheen BA, Mucha A, Morris LO, et al. Vestibular rehabilitation for dizziness and balance disorders after concussion. *J Neural Phys Ther.* 2010;34:87-93. <https://doi.org/10.1097/NPT.0b013e3181d1de568>
- Asama Y, Goto F, Tsutsumi T, Ogawa K. Objective evaluation of neck muscle tension and static balance in patients with chronic dizziness. *Acta Otolaryngol.* 2012;132:1168-1171. <https://doi.org/10.3109/00016489.2012.699197>
- Bagust J. Assessment of verticality perception by a rod-and-frame test: preliminary observations on the use of a computer monitor and video eye glasses. *Arch Phys Med Rehabil.* 2005;86:1062-1064. <https://doi.org/10.1016/j.apmr.2004.05.022>
- Bahat HS, Chen X, Reznik D, Kodesh E, Treleaven J. Interactive cervical motion kinematics: sensitivity, specificity and clinically significant values for identifying kinematic impairments in patients with chronic neck pain. *Man Ther.* 2015;20:295-302. <https://doi.org/10.1016/j.math.2014.10.002>
- Baloh R, Halmagyi G. *Disorders of the Vestibular System.* New York, NY: Oxford University Press; 1996.
- Barnett BP, Singman EL. Vision concerns after mild traumatic brain injury. *Curr Treat Options Neurol.* 2015;17:329. <https://doi.org/10.1007/s11940-014-0329-y>
- Bexander CS, Hodges PW. Cervico-ocular coordination during neck rotation is distorted in people with whiplash-associated disorders. *Exp Brain Res.* 2012;217:67-77. <https://doi.org/10.1007/s00221-011-2973-8>
- Bianco A, Pomara F, Petrucci M, et al. Postural stability in subjects with whiplash injury symptoms: results of a pilot study. *Acta Otolaryngol.* 2014;134:947-951. <https://doi.org/10.3109/00016489.2014.906749>
- Biffi WL, Moore EE, Elliott JP, et al. The devastating potential of blunt vertebral arterial injuries. *Ann Surg.* 2000;231:672-681.
- Broglio SP, Collins MW, Williams RM, Mucha A, Kontos AP. Current and emerging rehabilitation for concussion: a review of the evidence. *Clin Sports Med.* 2015;34:213-231. <https://doi.org/10.1016/j.csm.2014.12.005>
- Brown S. Effect of whiplash injury on accommodation. *Clin Exp Ophthalmol.* 2003;31:424-429. <https://doi.org/10.1046/j.1442-9071.2003.00690.x>
- Chen X, Treleaven J. The effect of neck torsion on joint position error in subjects with chronic neck pain. *Man Ther.* 2013;18:562-567. <https://doi.org/10.1016/j.math.2013.05.015>
- Ciavarro GL, Nozza M, Zaccheddu M, Andreoni G, Alpini D, Santambrogio GC. Assessment of whiplash injuries through 3D digital CranioCorpoGraphy [abstract]. *J Biomech.* 2006;39:S149. [https://doi.org/10.1016/S0021-9290\(06\)83500-1](https://doi.org/10.1016/S0021-9290(06)83500-1)
- Cobo EP, García-Alsina J, Almazán CG, et al. [Postural control disorders in initial phases of whiplash]. *Med Clin (Barc).* 2009;132:616-620. <https://doi.org/10.1016/j.medcli.2008.11.039>
- Cobo EP, Mesquida ME, Fanegas EP, et al. What factors have influence on persistence of neck pain after a whiplash? *Spine (Phila Pa 1976).* 2010;35:E338-E343. <https://doi.org/10.1097/BRS.0b013e3181c9b075>
- Cohen JM, Bigal ME, Newman LC. Migraine and vestibular symptoms—identifying clinical features that predict “vestibular migraine”. *Headache.* 2011;51:1393-1397. <https://doi.org/10.1111/j.1526-4610.2011.01934.x>
- Cohen JM, Newman LC, Bigal ME. Classifying vestibular migraine: demographics, associated features, and triggers [abstract]. *Cephalalgia.* 2009;29 suppl 1:162-163. <https://doi.org/10.1111/j.1468-2982.2009.01960.x>
- Cornell BD, Olivier E, Munoz DP. Neck muscle responses to stimulation of monkey superior colliculus. I. Topography and manipulation of stimulation parameters. *J Neurophysiol.* 2002;88:1980-1999.
- Côté JN, Patenaude I, St-Onge N, Fung J. Whiplash-associated disorders affect postural reactions to antero-posterior support surface translations during sitting. *Gait Posture.* 2009;29:603-611. <https://doi.org/10.1016/j.gaitpost.2008.12.014>
- Daenen L, Nijs J, Roussel N, Wouters K, Cras P. Altered perception of distorted visual feedback occurs soon after whiplash injury: an experimental study of central nervous system processing. *Pain Physician.* 2012;15:405-413.
- Daenen L, Nijs J, Roussel N, Wouters K, Van Loo M, Cras P. Sensorimotor incongruence exacerbates symptoms in patients with chronic whiplash associated disorders: an experimental study. *Rheumatology (Oxford).* 2012;51:1492-1499. <https://doi.org/10.1093/rheumatology/kes050>
- Della Casa E, Affolter Helbling J, Meichtry A, Luomajoki H, Kool J. Head-eye movement control tests in patients with chronic neck pain; inter-observer reliability and discriminative validity. *BMC Musculoskelet Disord.* 2014;15:16. <https://doi.org/10.1186/1471-2474-15-16>
- de Vries J, Ischebeck BK, Voogt LP, et al. Cervico-ocular reflex is increased in people with nonspecific neck pain. *Phys Ther.* 2016;96:1190-1195. <https://doi.org/10.2522/ptj.20150211>
- de Vries J, Ischebeck BK, Voogt LP, et al. Joint position sense error in people with neck pain: a systematic review. *Man Ther.* 2015;20:736-744. <https://doi.org/10.1016/j.math.2015.04.015>
- Dispenza F, De Stefano A, Mathur N, Croce A, Gallina S. Benign paroxysmal positional vertigo following whiplash injury: a myth or a reality? *Am J Otolaryngol.* 2011;32:376-380. <https://doi.org/10.1016/j.amjoto.2010.07.009>
- Dispenza F, Gargano R, Mathur N, Saraniti C, Gallina S. Analysis of visually guided eye movements in subjects after whiplash injury. *Auris Nasus Larynx.* 2011;38:185-189. <https://doi.org/10.1016/j.anl.2010.08.007>
- Ekvall Hansson E, Månsson NO, Ringsberg KA, Håkansson A. Dizziness among patients with whiplash-associated disorder: a randomized controlled trial. *J Rehabil Med.* 2006;38:387-390. <https://doi.org/10.1080/16501970600768992>
- Ekvall Hansson E, Persson L, Malmström EM. Influence of vestibular rehabilitation on neck pain and cervical range of motion among patients with whiplash-associated disorder: a randomized controlled trial. *J Rehabil Med.* 2013;45:906-910. <https://doi.org/10.2340/16501977-1197>
- Elliott J, Jull G, Noteboom JT, Darnell R, Galoway G, Gibbon WW. Fatty infiltration in the cervical extensor muscles in persistent whiplash-associated disorders: a magnetic resonance imaging analysis. *Spine (Phila Pa 1976).* 2006;31:E847-E855. <https://doi.org/10.1097/01.brs.0000240841.07050.34>
- Ellis MJ, Leddy JJ, Willer B. Physiologic, vestibulo-ocular and cervicogenic post-concussion disorders: an evidence-based classification system with directions for treatment. *Brain Inj.* 2015;29:238-248. <https://doi.org/10.3109/02699052.2014.965207>
- Ernst A, Basta D, Seidl RO, Todt I, Scherer H, Clarke A. Management of posttraumatic vertigo. *Otolaryngol Head Neck Surg.* 2005;132:554-558. <https://doi.org/10.1016/j.otohns.2004.09.034>
- Falla D. Unravelling the complexity of muscle impairment in chronic neck pain. *Man Ther.* 2004;9:125-133. <https://doi.org/10.1016/j.math.2004.05.003>
- Fattori B, Borsari C, Vannucci G, et al. Acupuncture treatment for balance disorders following whiplash injury. *Acupunct Electrother Res.* 1996;21:207-217. <https://doi.org/10.3727/036012996816356861>
- Ferrari R, Russell AS. Development of persistent neurologic symptoms in patients with simple neck sprain. *Arthritis Care Res.* 1999;12:70-76. [https://doi.org/10.1002/1529-0131\(199902\)12:1<70::AID-ART11>3.0.CO;2-B](https://doi.org/10.1002/1529-0131(199902)12:1<70::AID-ART11>3.0.CO;2-B)
- Field S, Treleaven J, Jull G. Standing balance: a comparison between idiopathic and whiplash-induced neck pain. *Man Ther.* 2008;13:183-191. <https://doi.org/10.1016/j.math.2006.12.005>
- Findling O, Schuster C, Sellner J, Ettlin T, Allum JH. Trunk sway in patients with and without, mild traumatic brain injury after whiplash injury. *Gait Posture.* 2011;34:473-478. <https://doi.org/10.1016/j.gaitpost.2011.06.021>
- Fischer AJ, Huygen PL, Folgering HT, Verhagen WI, Theunissen EJ. Vestibular hyperreactivity and hyperventilation after whiplash injury. *J Neurol Sci.* 1995;132:35-43. [https://doi.org/10.1016/0022-510X\(95\)00118-L](https://doi.org/10.1016/0022-510X(95)00118-L)
- Freitag P, Greenlee MW, Wachter K, Ettlin TM,

Radue EW. fMRI response during visual motion stimulation in patients with late whiplash syndrome. *Neurorehabil Neural Repair*. 2001;15:31-37. <https://doi.org/10.1177/154596830101500105>

39. Furman JM, Jacob RG. A clinical taxonomy of dizziness and anxiety in the otoneurological setting. *J Anxiety Disord*. 2001;15:9-26. [https://doi.org/10.1016/S0887-6185\(00\)00040-2](https://doi.org/10.1016/S0887-6185(00)00040-2)

40. Geiger G, Aliyev RM. Beschleunigungsverletzung der Halswirbelsäule in Abhängigkeit vom Unfallmechanismus: Neurootologische differentialdiagnostische Befunde. *Unfallchirurg*. 2012;115:629-634. <https://doi.org/10.1007/s00113-011-2151-2>

41. Gimse R, Björger IA, Tjell C, Tyssedal JS, Bø K. Reduced cognitive functions in a group of whiplash patients with demonstrated disturbances in the posture control system. *J Clin Exp Neuropsychol*. 1997;19:838-849. <https://doi.org/10.1080/01688639708403764>

42. Green W, Ciuffreda KJ, Thiagarajan P, Szymonowicz D, Ludlam DP, Kapoor N. Accommodation in mild traumatic brain injury. *J Rehabil Res Dev*. 2010;47:183-199. <https://doi.org/10.1682/JRRD.2009.04.0041>

43. Grimm RJ. Inner ear injuries in whiplash. *J Whiplash Relat Disord*. 2002;1:65-75. https://doi.org/10.3109/J180v01n01_06

44. Grip H, Jull G, Treleaven J. Head eye co-ordination using simultaneous measurement of eye in head and head in space movements: potential for use in subjects with a whiplash injury. *J Clin Monit Comput*. 2009;23:31-40. <https://doi.org/10.1007/s10877-009-9160-5>

45. Gurley JM, Hujsak BD, Kelly JL. Vestibular rehabilitation following mild traumatic brain injury. *NeuroRehabilitation*. 2013;32:519-528. <https://doi.org/10.3233/NRE-130874>

46. Heikkilä H, Johansson M, Wenngren BI. Effects of acupuncture, cervical manipulation and NSAID therapy on dizziness and impaired head repositioning of suspected cervical origin: a pilot study. *Man Ther*. 2000;5:151-157. <https://doi.org/10.1054/math.2000.0357>

47. Heikkilä HV, Wenngren BI. Cervicocephalic kinesthetic sensibility, active range of cervical motion, and oculomotor function in patients with whiplash injury. *Arch Phys Med Rehabil*. 1998;79:1089-1094. [https://doi.org/10.1016/S0003-9993\(98\)90176-9](https://doi.org/10.1016/S0003-9993(98)90176-9)

48. Heitger MH, Jones RD, Macleod AD, Snell DL, Frampton CM, Anderson TJ. Impaired eye movements in post-concussion syndrome indicate suboptimal brain function beyond the influence of depression, malingering or intellectual ability. *Brain*. 2009;132:2850-2870. <https://doi.org/10.1093/brain/awp181>

49. Herdman S. *Vestibular Rehabilitation*. 2nd ed. Philadelphia, PA: F.A. Davis; 2000.

50. Hildingsson C, Toolanen G. Outcome after soft-tissue injury of the cervical spine. A prospective study of 93 car-accident victims. *Acta Orthop Scand*. 1990;61:357-359. <https://doi.org/10.3109/17453679008993536>

51. Hildingsson C, Wenngren BI, Toolanen G. Eye motility dysfunction after soft-tissue injury of the cervical spine: a controlled, prospective study of 38 patients. *Acta Orthop Scand*. 1993;64:129-132. <https://doi.org/10.3109/17453679308994552>

52. Humphreys BK, Irgens PM. The effect of a rehabilitation exercise program on head repositioning accuracy and reported levels of pain in chronic neck pain subjects. *J Whiplash Relat Disord*. 2002;1:99-112. https://doi.org/10.3109/J180v01n01_09

53. Imai T, Higashi-Shingai K, Takimoto Y, Masumura C, Hattori K, Inohara H. New scoring system of an interview for the diagnosis of benign paroxysmal positional vertigo. *Acta Otolaryngol*. 2016;136:283-288. <https://doi.org/10.3109/00016489.2015.1121547>

54. Janssen M, Ischebeck BK, de Vries J, Kleinrensink GJ, Frens MA, van der Geest JN. Smooth pursuit eye movement deficits in patients with whiplash and neck pain are modulated by target predictability. *Spine (Phila Pa 1976)*. 2015;40:E1052-E1057. <https://doi.org/10.1097/BRS.0000000000001016>

55. Jull G, Sterling M, Falla D, Treleaven J, O'Leary S. *Whiplash, Headache, and Neck Pain: Research-Based Directions for Physical Therapies*. Edinburgh, UK: Elsevier/Churchill Livingstone; 2008.

56. Kloen P, Patterson JD, Wintman BI, Ozuna RM, Brick GW. Closed cervical spine trauma associated with bilateral vertebral artery injuries. *Arch Orthop Trauma Surg*. 1999;119:478-481. <https://doi.org/10.1007/s004020050027>

57. Knox JJ, Beilstein DJ, Charles SD, et al. Changes in head and neck position have a greater effect on elbow joint position sense in people with whiplash-associated disorders. *Clin J Pain*. 2006;22:512-518. <https://doi.org/10.1097/01.ajp.0000210997.53082.c9>

58. Kongsted A, Jørgensen LV, Bendix T, Korsholm L, Leboeuf-Yde C. Are smooth pursuit eye movements altered in chronic whiplash-associated disorders? A cross-sectional study. *Clin Rehabil*. 2007;21:1038-1049. <https://doi.org/10.1177/0269215507075519>

59. Kristjansson E, Hardardottir L, Asmundardottir M, Gudmundsson K. A new clinical test for cervicocephalic kinesthetic sensibility: "The Fly". *Arch Phys Med Rehabil*. 2004;85:490-495. [https://doi.org/10.1016/S0003-9993\(03\)00619-1](https://doi.org/10.1016/S0003-9993(03)00619-1)

60. Kristjansson E, Oddsdottir GL. "The Fly": a new clinical assessment and treatment method for deficits of movement control in the cervical spine: reliability and validity. *Spine (Phila Pa 1976)*. 2010;35:E1298-E1305. <https://doi.org/10.1097/BRS.0b013e3181e7fc0a>

61. Laborey M, Masson F, Ribéreau-Gayon R, Zongo D, Salmi LR, Lagarde E. Specificity of postconcussion symptoms at 3 months after mild traumatic brain injury: results from a comparative cohort study. *J Head Trauma Rehabil*. 2014;29:E28-E36. <https://doi.org/10.1097/HTR.0b013e318280f896>

62. Leddy JJ, Baker JG, Merchant A, et al. Brain or strain? Symptoms alone do not distinguish physi-

ologic concussion from cervical/vestibular injury. *Clin J Sport Med*. 2015;25:237-242. <https://doi.org/10.1097/JSM.0000000000000128>

63. Lee JW, Jung JY, Chung YS, Suh MW. Clinical manifestation and prognosis of vestibular migraine according to the vestibular function test results. *Korean J Audiol*. 2013;17:18-22. <https://doi.org/10.7874/kja.2013.17.1.18>

64. Lempert T, Olesen J, Furman J, et al. Migraine vestibulaire: critères diagnostiques. Document consensuel de la Société Bárány et de la Société internationale des céphalées. *Rev Neural (Paris)*. 2014;170:401-406. <https://doi.org/10.1016/j.neuro.2013.05.010>

65. Lempert T, Olesen J, Furman J, et al. Vestibular migraine: diagnostic criteria. *J Vestib Res*. 2012;22:167-172. <https://doi.org/10.3233/VES-2012-0453>

66. Le Pera D, Graven-Nielsen T, Valeriani M, et al. Inhibition of motor system excitability at cortical and spinal level by tonic muscle pain. *Clin Neurophysiol*. 2001;112:1633-1641. [https://doi.org/10.1016/S1388-2457\(01\)00631-9](https://doi.org/10.1016/S1388-2457(01)00631-9)

67. L'Heureux-Lebeau B, Godbout A, Berbiche D, Saliba I. Evaluation of paraclinical tests in the diagnosis of cervicogenic dizziness. *Otol Neurotol*. 2014;35:1858-1865. <https://doi.org/10.1097/MAO.0000000000000506>

68. Madeleine P, Prietzel H, Sværre H, Arendt-Nielsen L. Quantitative posturography in altered sensory conditions: a way to assess balance instability in patients with chronic whiplash injury. *Arch Phys Med Rehabil*. 2004;85:432-438. <https://doi.org/10.1016/j.apmr.2003.03.003>

69. Marshall CM, Vernon H, Leddy JJ, Baldwin BA. The role of the cervical spine in post-concussion syndrome. *Phys Sportsmed*. 2015;43:274-284. <https://doi.org/10.1080/00913847.2015.1064301>

70. Montfoort I, Kelders WP, van der Geest JN, et al. Interaction between ocular stabilization reflexes in patients with whiplash injury. *Invest Ophthalmol Vis Sci*. 2006;47:2881-2884. <https://doi.org/10.1167/iov.05-1561>

71. Montfoort I, Van Der Geest JN, Slijper HP, De Zeeuw CI, Frens MA. Adaptation of the cervico- and vestibulo-ocular reflex in whiplash injury patients. *J Neurotrauma*. 2008;25:687-693. <https://doi.org/10.1089/neu.2007.0314>

72. Morganti LO, Salmito MC, Duarte JA, Bezerra KC, Simões JC, Ganança FF. Vestibular migraine: clinical and epidemiological aspects. *Braz J Otorhinolaryngol*. 2016;82:397-402. <https://doi.org/10.1016/j.bjorl.2015.06.003>

73. Mosimann UP, Müri RM, Felblinger J, Radanov BP. Saccadic eye movement disturbances in whiplash patients with persistent complaints. *Brain*. 2000;123 pt 4:828-835. <https://doi.org/10.1093/brain/123.4.828>

74. Nacci A, Ferrazzi M, Berrettini S, et al. Vestibular and stabilometric findings in whiplash injury and minor head trauma. *Acta Otorhinolaryngol Ital*. 2011;31:378-389.

75. Oddsdottir G. *Cervical Induced Balance Disturbances After Motor Vehicle Collisions: The*

Efficacy of Two Successive Physical Treatment Approaches [thesis]. Reykjavik, Iceland: University of Iceland; 2006.

76. Oddsdóttir GL, Kristjánsson E. Two different courses of impaired cervical kinaesthesia following a whiplash injury. A one-year prospective study. *Man Ther*. 2012;17:60-65. <https://doi.org/10.1016/j.math.2011.08.009>
77. Oka H, Matsudaira K, Fujii T, et al. Risk factors for prolonged treatment of whiplash-associated disorders. *PLoS One*. 2015;10:e0132191. <https://doi.org/10.1371/journal.pone.0132191>
78. Padula WV, Argyris S. Post trauma vision syndrome and visual midline shift syndrome. *NeuroRehabilitation*. 1996;6:165-171. <https://doi.org/10.3233/NRE-1996-6302>
79. Passatore M, Roatta S. Influence of sympathetic nervous system on sensorimotor function: whiplash associated disorders (WAD) as a model. *Eur J Appl Physiol*. 2006;98:423-449. <https://doi.org/10.1007/s00421-006-0312-8>
80. Pearce KL, Sufirinko A, Lau BC, Henry L, Collins MW, Kontos AP. Near point of convergence after a sport-related concussion: measurement reliability and relationship to neuro-cognitive impairment and symptoms. *Am J Sports Med*. 2015;43:3055-3061. <https://doi.org/10.1177/03635465150606430>
81. Pedler A, Motlagh H, Sterling M. Laterality judgments are not impaired in patients with chronic whiplash associated disorders. *Man Ther*. 2013;18:72-76. <https://doi.org/10.1016/j.math.2012.07.006>
82. Peterson BW. Current approaches and future directions to understanding control of head movement. *Prog Brain Res*. 2004;143:369-381. [https://doi.org/10.1016/S0079-6123\(03\)43035-5](https://doi.org/10.1016/S0079-6123(03)43035-5)
83. Phillips LA, Carroll LJ, Cassidy JD, Côté P. Whiplash-associated disorders: who gets depressed? Who stays depressed? *Eur Spine J*. 2010;19:945-956. <https://doi.org/10.1007/s00586-010-1276-2>
84. Provinciali L, Baroni M, Illuminati L, Ceravolo MG. Multimodal treatment to prevent the late whiplash syndrome. *Scand J Rehabil Med*. 1996;28:105-111.
85. Reid SA, Callister R, Katekar MG, Rivett DA. Effects of cervical spine manual therapy on range of motion, head repositioning, and balance in participants with cervicogenic dizziness: a randomized controlled trial. *Arch Phys Med Rehabil*. 2014;95:1603-1612. <https://doi.org/10.1016/j.apmr.2014.04.009>
86. Reid SA, Callister R, Snodgrass SJ, Katekar MG, Rivett DA. Manual therapy for cervicogenic dizziness: long-term outcomes of a randomised trial. *Man Ther*. 2015;20:148-156. <https://doi.org/10.1016/j.math.2014.08.003>
87. Reneker JC, Moughiman MC, Cook CE. The diagnostic utility of clinical tests for differentiating between cervicogenic and other causes of dizziness after a sports-related concussion: an international Delphi study. *J Sci Med Sport*. 2015;18:366-372. <https://doi.org/10.1016/j.jsams.2014.05.002>
88. Revel M, Andre-Deshays C, Minguet M. Cervicocephalic kinesthetic sensibility in patients with cervical pain. *Arch Phys Med Rehabil*. 1991;72:288-291.
89. Richter HO. Neck pain brought into focus. *Work*. 2014;47:413-418. <https://doi.org/10.3233/WOR-131776>
90. Richter HO, Röjjezon U, Björklund M, Djupsjöbacka M. Long-term adaptation to neck/shoulder pain and perceptual performance in a hand laterality motor imagery test. *Perception*. 2010;39:119-130. <https://doi.org/10.1068/p6418>
91. Sandlund J, Djupsjöbacka M, Ryhed B, Hamberg J, Björklund M. Predictive and discriminative value of shoulder proprioception tests for patients with whiplash-associated disorders. *J Rehabil Med*. 2006;38:44-49. <https://doi.org/10.1080/16501970510042847>
92. Sandlund J, Röjjezon U, Björklund M, Djupsjöbacka M. Acuity of goal-directed arm movements to visible targets in chronic neck pain. *J Rehabil Med*. 2008;40:366-374. <https://doi.org/10.2340/16501977-0175>
93. Schneider KJ, Meeuwisse WH, Nettel-Aguirre A, et al. Cervicovestibular rehabilitation in sport-related concussion: a randomised controlled trial. *Br J Sports Med*. 2014;48:1294-1298. <https://doi.org/10.1136/bjsports-2013-093267>
94. Shumway-Cook A, Horak FB. Assessing the influence of sensory interaction of balance. Suggestion from the field. *Phys Ther*. 1986;66:1548-1550. <https://doi.org/10.1093/ptj/66.10.1548>
95. Silva AG, Cruz AL. Standing balance in patients with whiplash-associated neck pain and idiopathic neck pain when compared with asymptomatic participants: a systematic review. *Physiother Theory Pract*. 2013;29:1-18. <https://doi.org/10.3109/09593985.2012.677111>
96. Sjöström H, Allum JH, Carpenter MG, Adkin AL, Honegger F, Ettlin T. Trunk sway measures of postural stability during clinical balance tests in patients with chronic whiplash injury symptoms. *Spine (Phila Pa 1976)*. 2003;28:1725-1734. <https://doi.org/10.1097/01.BRS.0000083170.34304.A3>
97. Solarino B, Coppola F, Di Vella G, Corsalini M, Quaranta N. Vestibular evoked myogenic potentials (VEMPs) in whiplash injury: a prospective study. *Acta Otolaryngol*. 2009;129:976-981. <https://doi.org/10.1080/00016480802527552>
98. Stålnacke BM. Postconcussion symptoms in patients with injury-related chronic pain. *Rehabil Res Pract*. 2012;2012:528265. <https://doi.org/10.1155/2012/528265>
99. Stapley PJ, Beretta MV, Dalla Toffola E, Schieppati M. Neck muscle fatigue and postural control in patients with whiplash injury. *Clin Neurophysiol*. 2006;117:610-622. <https://doi.org/10.1016/j.clinph.2005.11.007>
100. Sterling M, Jull G, Vicenzino B, Kenardy J, Darnell R. Development of motor system dysfunction following whiplash injury. *Pain*. 2003;103:65-73. [https://doi.org/10.1016/S0304-3959\(02\)00420-7](https://doi.org/10.1016/S0304-3959(02)00420-7)
101. Stokell R, Yu A, Williams K, Treleaven J. Dynamic and functional balance tasks in subjects with persistent whiplash: a pilot trial. *Man Ther*. 2011;16:394-398. <https://doi.org/10.1016/j.math.2011.01.012>
102. Storaci R, Manelli A, Schiavone N, Mangia L, Prigione G, Sangiorgi S. Whiplash injury and oculomotor dysfunctions: clinical-posturographic correlations. *Eur Spine J*. 2006;15:1811-1816. <https://doi.org/10.1007/s00586-006-0085-0>
103. Swait G, Rushton AB, Miall RC, Newell D. Evaluation of cervical proprioceptive function: optimizing protocols and comparison between tests in normal subjects. *Spine (Phila Pa 1976)*. 2007;32:E692-E701. <https://doi.org/10.1097/BRS.0b013e31815a5a1b>
104. Szabo T, Welcher J. Human Subject Kinematics and Electromyographic Activity During Low Speed Rear Impacts. SAE Technical Paper 962432. Warrendale, PA: SAE International; 1996.
105. Takasaki H, Chien CW, Johnston V, Treleaven J, Jull G. Validity and reliability of the perceived deficit questionnaire to assess cognitive symptoms in people with chronic whiplash-associated disorders. *Arch Phys Med Rehabil*. 2012;93:1774-1781. <https://doi.org/10.1016/j.apmr.2012.05.013>
106. Takasaki H, Treleaven J. Construct validity and test-retest reliability of the Fatigue Severity Scale in people with chronic neck pain. *Arch Phys Med Rehabil*. 2013;94:1328-1334. <https://doi.org/10.1016/j.apmr.2012.12.013>
107. Taylor J, Taylor M. Cervical spinal injuries: an autopsy study of 109 blunt injuries. *J Musculoskelet Pain*. 1996;4:61-79.
108. Thomas LC. Cervical arterial dissection: an overview and implications for manipulative therapy practice. *Man Ther*. 2016;21:2-9. <https://doi.org/10.1016/j.math.2015.07.008>
109. Thomas LC, Rivett DA, Attia JR, Levi C. Risk factors and clinical presentation of cervical arterial dissection: preliminary results of a prospective case-control study. *J Orthop Sports Phys Ther*. 2015;45:503-511. <https://doi.org/10.2519/jospt.2015.5877>
110. Thunberg J, Hellström F, Sjölander P, Bergenheim M, Wenngren B, Johansson H. Influences on the fusimotor-muscle spindle system from chemosensitive nerve endings in cervical facet joints in the cat: possible implications for whiplash induced disorders. *Pain*. 2001;91:15-22. [https://doi.org/10.1016/S0304-3959\(00\)00415-2](https://doi.org/10.1016/S0304-3959(00)00415-2)
111. Tjell C, Rosenhall U. Smooth cervical neck torsion test: a specific test for cervicogenic dizziness. *Am J Otol*. 1998;19:76-81.
112. Tranter RM, Graham JR. A review of the otological aspects of whiplash injury. *J Forensic Leg Med*. 2009;16:53-55. <https://doi.org/10.1016/j.jflm.2008.09.001>
113. Treleaven J. Dizziness, unsteadiness, visual disturbances, and postural control: implications for the transition to chronic symptoms after a whiplash trauma. *Spine (Phila Pa 1976)*. 2011;36:S211-S217. <https://doi.org/10.1097/BRS.0b013e3182387f78>

114. Treleaven J. Sensorimotor disturbances in neck disorders affecting postural stability, head and eye movement control. *Man Ther.* 2008;13:2-11. <https://doi.org/10.1016/j.math.2007.06.003>
115. Treleaven J. Sensorimotor disturbances in neck disorders affecting postural stability, head and eye movement control—part 2: case studies. *Man Ther.* 2008;13:266-275. <https://doi.org/10.1016/j.math.2007.11.002>
116. Treleaven J. A tailored sensorimotor approach for management of whiplash associated disorders. A single case study. *Man Ther.* 2010;15:206-209. <https://doi.org/10.1016/j.math.2009.05.001>
117. Treleaven J, Jull G, Grip H. Head eye coordination and gaze stability in subjects with persistent whiplash associated disorders. *Man Ther.* 2011;16:252-257. <https://doi.org/10.1016/j.math.2010.11.002>
118. Treleaven J, Jull G, LowChoy N. The relationship of cervical joint position error to balance and eye movement disturbances in persistent whiplash. *Man Ther.* 2006;11:99-106. <https://doi.org/10.1016/j.math.2005.04.003>
119. Treleaven J, Jull G, Lowchoy N. Smooth pursuit neck torsion test in whiplash-associated disorders: relationship to self-reports of neck pain and disability, dizziness and anxiety. *J Rehabil Med.* 2005;37:219-223. <https://doi.org/10.1080/16501970410024299>
120. Treleaven J, Jull G, Lowchoy N. Standing balance in persistent whiplash: a comparison between subjects with and without dizziness. *J Rehabil Med.* 2005;37:224-229. <https://doi.org/10.1080/16501970510027989>
121. Treleaven J, Jull G, Sterling M. Dizziness and unsteadiness following whiplash injury: characteristic features and relationship with cervical joint position error. *J Rehabil Med.* 2003;35:36-43. <https://doi.org/10.1080/16501970306109>
122. Treleaven J, LowChoy N, Darnell R, Panizza B, Brown-Rothwell D, Jull G. Comparison of sensorimotor disturbance between subjects with persistent whiplash-associated disorder and subjects with vestibular pathology associated with acoustic neuroma. *Arch Phys Med Rehabil.* 2008;89:522-530. <https://doi.org/10.1016/j.apmr.2007.11.002>
123. Treleaven J, Peterson G, Ludvigsson ML, Kammerlind AS, Peolsson A. Balance, dizziness and proprioception in patients with chronic whiplash associated disorders complaining of dizziness: a prospective randomized study comparing three exercise programs. *Man Ther.* 2016;22:122-130. <https://doi.org/10.1016/j.math.2015.10.017>
124. Treleaven J, Takasaki H. Characteristics of visual disturbances reported by subjects with neck pain. *Man Ther.* 2014;19:203-207. <https://doi.org/10.1016/j.math.2014.01.005>
125. Treleaven J, Takasaki H. High variability of the subjective visual vertical test of vertical perception, in some people with neck pain – should this be a standard measure of cervical proprioception? *Man Ther.* 2015;20:183-188. <https://doi.org/10.1016/j.math.2014.08.005>
126. Treleaven J, Takasaki H, Grip H. Trunk-head coordination in neck pain subjects [abstract]. *J Orthop Sports Phys Ther.* 2012;42:A65. <https://doi.org/10.2519/jospt.2012.0302>
127. Williams K, Tarmizi A, Treleaven J. Use of neck torsion as a specific test of neck related postural instability. *Musculosket Sci Pract.* 2017;29:115-119. <http://doi.org/10.1016/j.msksp.2017.03.012>
128. Ventura RE, Balcer LJ, Galetta SL, Rucker JC. Ocular motor assessment in concussion: current status and future directions. *J Neurol Sci.* 2016;361:79-86. <https://doi.org/10.1016/j.jns.2015.12.010>
129. Wenngren BI, Pettersson K, Löwenhielm G, Hildingsson C. Eye motility and auditory brainstem response dysfunction after whiplash injury. *Acta Otolaryngol.* 2002;122:276-283. <https://doi.org/10.1080/000164802753648150>
130. Wieser T, Wolff R, Hoffmann KP, Schulte-Mattler W, Zierz S. Persistent ocular motor disturbances in migraine without aura. *Neurol Sci.* 2004;25:8-12. <https://doi.org/10.1007/s10072-004-0218-6>
131. Wilhelmsen K, Kvåle A. Examination and treatment of patients with unilateral vestibular damage, with focus on the musculoskeletal system: a case series. *Phys Ther.* 2014;94:1024-1033. <https://doi.org/10.2522/ptj.20130070>
132. Woodhouse A, Stavdahl Ø, Vasseljen O. Irregular head movement patterns in whiplash patients during a trajectory task. *Exp Brain Res.* 2010;201:261-270. <https://doi.org/10.1007/s00221-009-2033-9>
133. Yu LJ, Stokell R, Treleaven J. The effect of neck torsion on postural stability in subjects with persistent whiplash. *Man Ther.* 2011;16:339-343. <https://doi.org/10.1016/j.math.2010.12.006>



MORE INFORMATION
WWW.JOSPT.ORG

SEND Letters to the Editor-in-Chief

JOSPT welcomes **letters related to professional issues or articles published in the Journal**. The Editor-in-Chief reviews and selects letters for publication based on the topic's relevance, importance, appropriateness, and timeliness. Letters should include a summary statement of any conflict of interest, including financial support related to the issue addressed. In addition, letters are copy edited, and the correspondent is not typically sent a version to approve. Letters to the Editor-in-Chief should be sent electronically to josp@josp.org. Authors of the relevant manuscript are given the opportunity to respond to the content of the letter.